

DIASTEMATOMYELIA (SPLIT CORD MALFORMATION)

CARMEN CRIVII, IULIAN OPINCARIU

Department of Anatomy-Embryology, University of Medicine and Pharmacy
"Iuliu Hațieganu" Cluj-Napoca, Romania

Abstract

The paper presents a case of a Split Cord Malformation (SCM), also called diastematomyelia, associated with spina bifida occulta. It is a complex defect which occurs during the 4th week of development. SCM is a rare form of spinal dysraphism, which occurs as a result of the presence of an accessory neuroenteric canal. In this case MRI showed a bony septum which splits the spinal cord into two hemicords – each in it's own dural sac, to the level of the T12-L2, and a Neural Tube Defect (NTD) – spina bifida occulta, to the level of the L4-L5.

Keywords: diastematomyelia, diplomyelia, spinal cord malformation.

DIASTEMATOMIELIA (BIFURCARE A MĂDUVEI SPINĂRII)

Rezumat

Lucrarea de față prezintă un caz de bifurcare a măduvei spinării, malformație cunoscută sub numele de diastematomieli, asociată cu spina bifida ocultă. Diastematomieli este o malformație complexă, ce apare în timpul celei de-a 4-a săptămâni de dezvoltare embrionară. Această formă rară de dismorfism medular este determinată de dezvoltarea unui canal neuroenteric accesoriu. În cazul de față, investigațiile RMN au arătat prezența unui sept osos care a determinat bifurcarea măduvei spinării la nivelul vertebrelor T12-L2, iar la nivelul L4-L5 s-a constatat prezența unui defect de tub neural – spina bifida ocultă.

Cuvinte cheie: diastematomieli, diplomieli, malformații ale măduvei spinării.

INTRODUCTION

First described in 1837 by Ollivier [1], diastematomyelia is a rare congenital anomaly of the spinal cord, involving a dysraphic lesion. The term is from the Greek "diastema" (cleft) and "myelos" (marrow or medulla). Female are affected much more than the male. Diastematomyelia is described by a sagittal split in the spinal cord – an osseous or fibro-cartilaginous septum in the central portion of the spinal canal which produces a complete or incomplete sagittal division of the spinal cord into two hemicords. The lesion usually occurs between T9 and L3: to the level of L1 – L3 (50%), or to the level of T7-T12 (25%). Cervical and sacral diastematomyelia are very rare entities.

More than 75% of the patients have the conus medullaris situated below L2 and more than 50% have the thickening of the filum terminale. Usually the two

hemicords reunite caudally to the split, but there are cases when the split can not reunite distally to the lesion – is the true duplication of the spinal cord or diplomyelia.

In 1992, in an effort to provide a classification scheme, Pang and Dias [1,2], building on the theories of Bremer [3] and the classification used by James and Lassman [4, cited by 5], suggested the two types of diastematomyelia:

- type I or external diastematomyelia – 40% of the patients – with an osseous or fibro-cartilaginous band which splits into two separate dural sacks; each hemicord contains the central canal and a pair of the anterior and posterior horns, giving rises to the ventral and dorsal spinal nerve roots; these patients are usually symptomatic;
- type II or internal diastematomyelia – 60% of the patients – present a single dural sac with two hemicords, but no spur; in general, these patients are asymptomatic.

These malformations can be isolated or in association with meningocele or meningomyelocele, neuroenteric cyst or dermoid. Other associations may include club foot, spinal cord lipoma, haemangioma overlying the spine, scoliosis, unilateral muscle wasting.

Manuscript received: 03.08.2011

Received in revised form: 20.08.2011

Accepted: 02.09.2011

Adress for correspondence: bianca.crivii@umfcluj.ro

CASE REPORT

A girl, aged 8 years, complaining of discomfort to the level of the lower limbs, with neurological dysfunctions of the lower limbs such as legs spasticity, involuntary flexion of the knees was send for diagnosis and evaluation. Physical examination revealed a child with an asymmetry of the lower limbs (the left foot smaller then the right foot), spasticity and atrophy of the lower limbs, flexion of both knees (accentuated to the level of the left knee). The examination of the back showed no evident abnormality, except an excess of hair in the lumbar area. Cardiovascular, pulmonary, and abdominal examinations were normal. Her past personal history included a low birth weight baby (2180 gr.) at 35 gestational weeks. Family history was unremarkable.

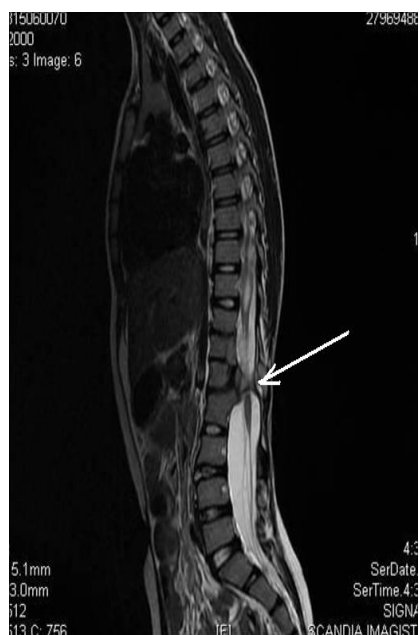

Fig. 1 A. Sagittal section through the spine – arrow indicates the bony septum to the level of T12-L2 which splits the spinal cord.

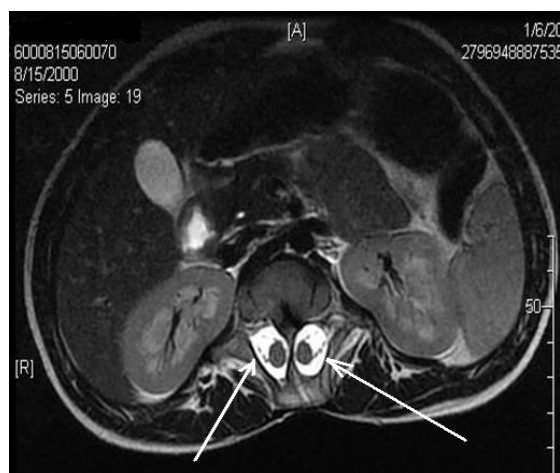


Fig. 1 B. Transverse section through the spine to the level of L2 – the arrows indicate the two hemicords, in there own dural sac.

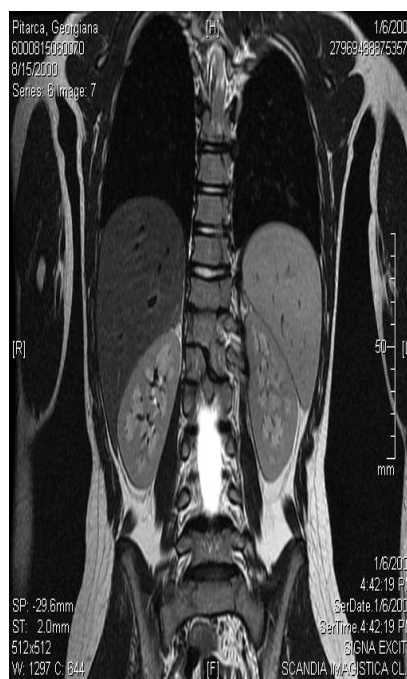

Fig. 2. Frontal section through the spine – vertebral malformations, more evident on the left part of the spine to the level of T11-L2 vertebrae.

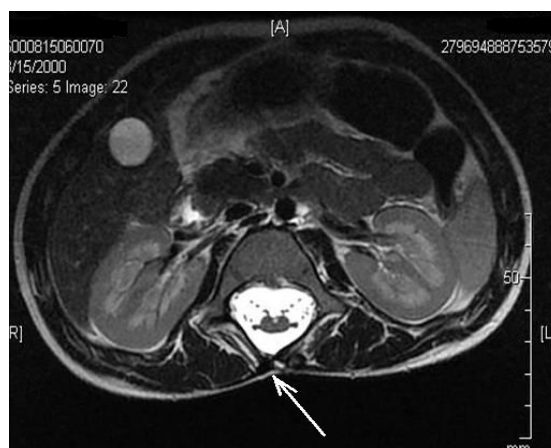


Fig. 3. Transverse section through the spine to the level of L5 – the arrow indicates the absence of the bony structure to the posterior part of the vertebral arch cover by the skin (spina bifida occulta).

MRI scan of the spine revealed the presence of a split cord between T12-L2 with a bony septum (Fig. 1A), in double dural sac (Fig. 1B), congenital vertebral anomalies associated with body vertebral hypoplasia to the level of T12-L2 (Fig. 2). To the level of L2-L3 there was a NTD - spina bifida occulta (Fig. 3). The right and left hemicords, approximately equal, are reunited to the level of L3.

The diagnosis in this case is: upper lumbar diastematomyelia type I, associated with low lumbar spina bifida occulta.

DISCUSSION

Diastematomyelia is a dysraphic lesion of the spine. The diagnosis has been more frequent since the advent of newer imagistic methods. MRI scanning is often the first step in the diagnosis. MRI gives the image of the spinal cord deformities and the vertebral anatomy. CT scan (combined myelographic and post-myelographic CT) allow the diagnostic with the detailed bone, intradural and extradural pathological anatomy of the spinal canal and the bony spur.

The symptoms of SCM can appear at any time of life, but the diagnosis is usually established during childhood. Asymptomatic presentations are similar to those of other forms of occult spinal dysraphism, the most prominent presentation being external cutaneous manifestations. Symptomatic cases often present with progressive signs and symptoms and are nonspecific (common for different causes of the cord tethering), the result of the tissue attachments that limit the movements of the spinal cord within the spinal column [1]. The disorders start in the childhood with weakness in the legs, low back pain, scoliosis, foot and/or spinal deformities. In time, during adulthood, the sensory and motor complaints are progressive. Tethered spinal cord syndrome is the result of the improper development of the neural tube during fetal time. The slow progressive lower limb neurological deficit can be prevented by surgical release of the tethered cord.

Prenatal diagnostic is possible in the early third trimester. The extra posterior echogenic focus between the fetal spinal laminae and the posterior elements is seen on prenatal sonograms regardless of whether there is a bony or cartilaginous spur [6]. Usually it is recommended to determine the α -fetoprotein level, to ensure that an open neural tube defect has not been shut out [7]. The prenatal diagnosis of the diastematomyelia and the associated pathology is important for the surgical management after birth.

The exact cause of diastematomyelia is unknown. The key to understand these malformations lies in properly appreciating the embryonic relationship between the developing neural tube and the endoderm during early development. This complex defect occurs during the 4th week of embryological development. Both types are thought to be caused by an abnormal, persistent neurenteric canal between the yolk sac and amnions and thus enables contact between the ectoderm and endoderm within the canal. This abnormal fistula splits later the neural canal and the notochord by forming an endomesenchymal tract. The persistence of parts of the tract, the entrapment of different structures within it, or both, explain the subsequent formation of associated malformations. For instance, the endodermal remnants predispose to the formation of neurenteric cysts and intestinal duplication; the lack of SCMs has low-lying conus and may have additional tethering lesions [8].

In a review of 45 cases by Russell et al. [9], 24

cases of diastematomyelia were noted to be in the lumbar region. Various precipitating factors have been implicated in their pathophysiology including trauma, spinal canal compression and strong stretching factors. All these factors contribute to a neurologic deficit in an already compromised neural canal. Some form of an associated congenital anomaly, or dysraphism of the vertebral column is a constant feature. Intramedullary epidermoid tumors of the spinal cord are rare and are believed to arise from the displacement of ectodermal cells during neural groove closure between the third and fifth weeks of embryonic life [10]. Intraspinal epidermoid tumors represent less than 1% of all intraspinal tumors in adults [11]. Occasionally they may be traumatic in nature, acquired as a late complication of multiple lumbar punctures [12]. Intraspinal epidermoid cysts generally predominate in the lumbar region, but intramedullary epidermoids are more common in the thoracic region [10].

The asymptomatic patients, which have been identified with diastematomyelia while being investigated for other issues, require just periodic neurological examinations. For the patients with neurological symptoms the surgical treatment presume the removal of the spur and the decompression of all nervous structures. Gan et al. made a study of the results after surgery treatment of 17 children with diastematomyelia. They conclude that despite improvement, all patients with established preoperative deficit still had residual neurological deficits [13].

CONCLUSION

The Split Cord Malformations cause traction on the spinal cord, which causes ischemia as well the local trauma of the cord. The results are neurological deficits. The diagnosis is suspected in the presence of cutaneous midline defects, muscular imbalance in the lower extremities, gait disturbances, deformities of the feet. The diagnostic is confirmed by MRI scans. Treatment must be based on a clear understanding of the underlying anomaly, the natural history, the etiology, and the procedure required decompression of neural elements and removal of bony spur.

References

1. Pang D, Dias MS, Ahab-Barmada M. Split cord malformation. I. A unified theory of embryogenesis for double spinal cord malformations. *Neurosurg*, 1992; 31: 451-480
2. Pang D. Split cord malformation, II: Clinical syndrome. *Neurosurg*, 1992; 31: 481-500
3. Bremer JL. Dorsal intestinal fistula: accessory neurenteric canal: diastematomyelia. *AMA Arch Pathol*, 1952; 54: 132-138
4. James C, Lassman L. Spina Bifida Occulta: Orthopedic, Radiological and Neurosurgical Aspects. London, Academic; 1981
5. Albright LA, Pollack IF, Adelson PD. Principles and Practice of Pediatric Neurosurgery, New York: Thieme Medical Publishers, 2nd Ed, 2008; 368-369

-
6. Anderson NG, Jordan S, MacFarlane MR, et al. Diastematomyelia: diagnosis by prenatal sonography. *Am J Roentgenol*, 1994; 163/4: 911-914
 7. Bulsara KR, Zomorodi AR, Enterline DS, et al. The value of magnetic resonance imaging in the evaluation of fatty filum terminale. *Neurosurg*, 2004; 54: 375-379
 8. Martin P. Diastematomyelia: a case report. *NZ J Physio*, 2007; 35(1):24-27
 9. Russell NA, Benoit BG, Joaquin AJ. Diastematomyelia in adults: a review. *Pediatr Neurosurg*, 1990-1991; 16: 252 -257
 10. Benzil DL, Epstein MH, Knuckey NW. Intramedullary epidermoid associated with an intramedullary spinal abscess secondary to a dermal sinus. *Neurosurg*, 1992; 30:118-121
 11. Lunardi P, Missori P, Gagliardi FM, et al. Long term results of the surgical treatment of spinal dermoid and epidermoid tumors. *Neurosurg*, 1989; 25: 860-864
 12. Halcrow SJ, Crawford PJ, Craft AW. Epidermoid spinal cord tumor after lumbar puncture. *Arch Dis Child*, 1985; 60: 978-979
 13. Gan YC, Sgouros S, Walh AR, et al. Diastematomyelia in children: treatment outcome and natural history of associated syringomyelia. *Child's Nerv Syst*, 2007, 23/5: 515-519